

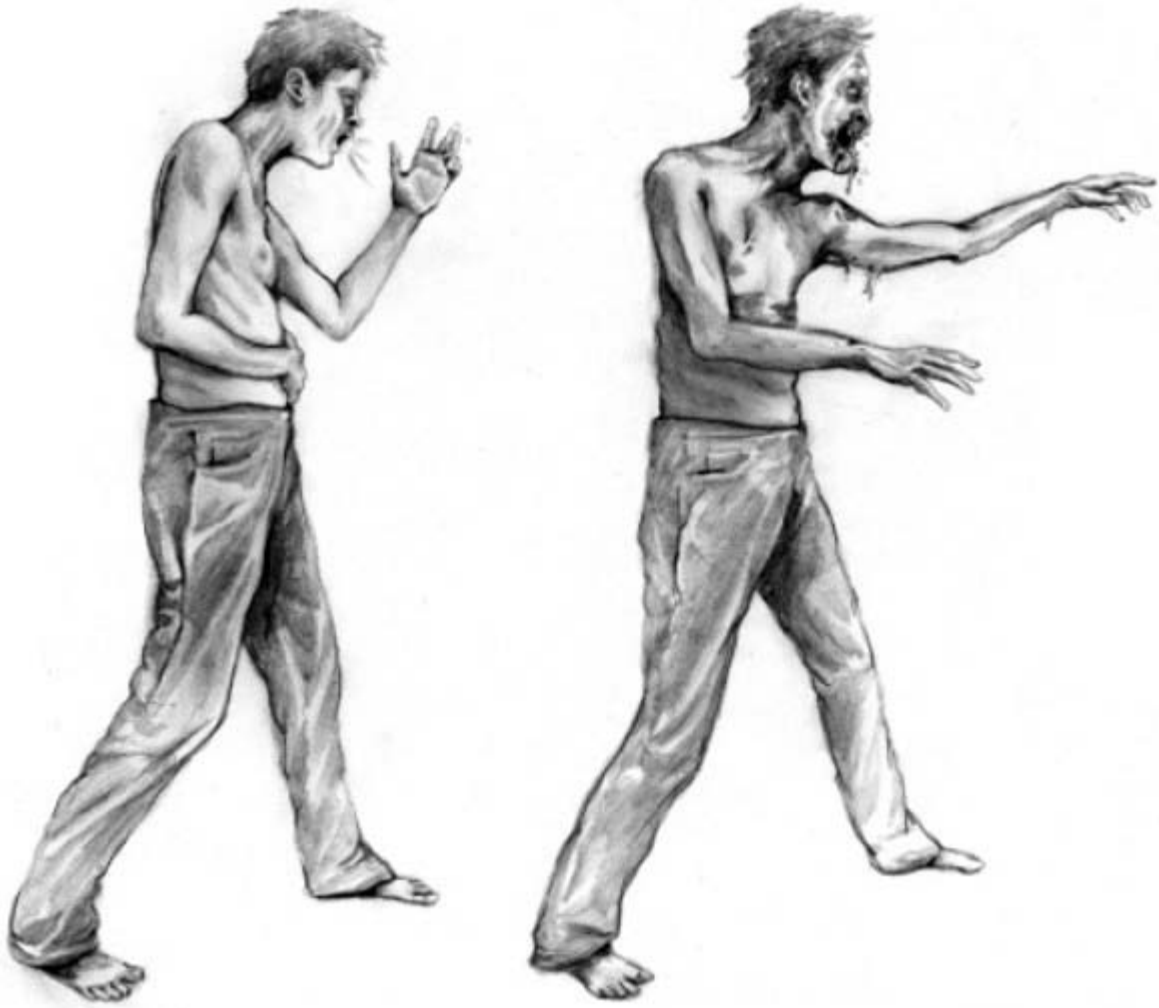THE ZOMBIE AUTOPSIES

SECRET NOTEBOOKS FROM THE APOCALYPSE

BY STEVEN C. SCHLOZMAN, M.D.

ILLUSTRATIONS BY ANDREA SPARACIO

Stages I and II



Stage I

Stage II

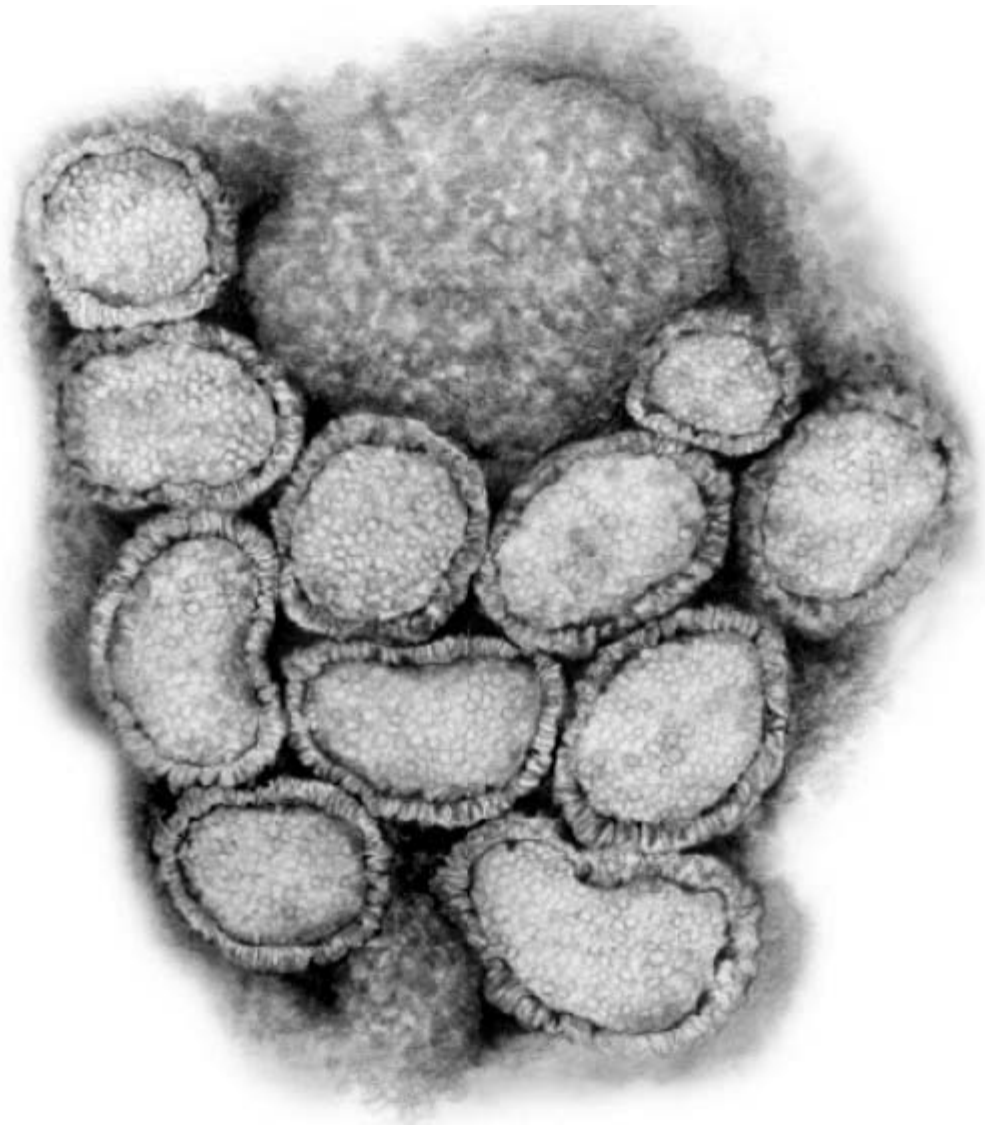
Stages III and IV



Stage III

Stage IV

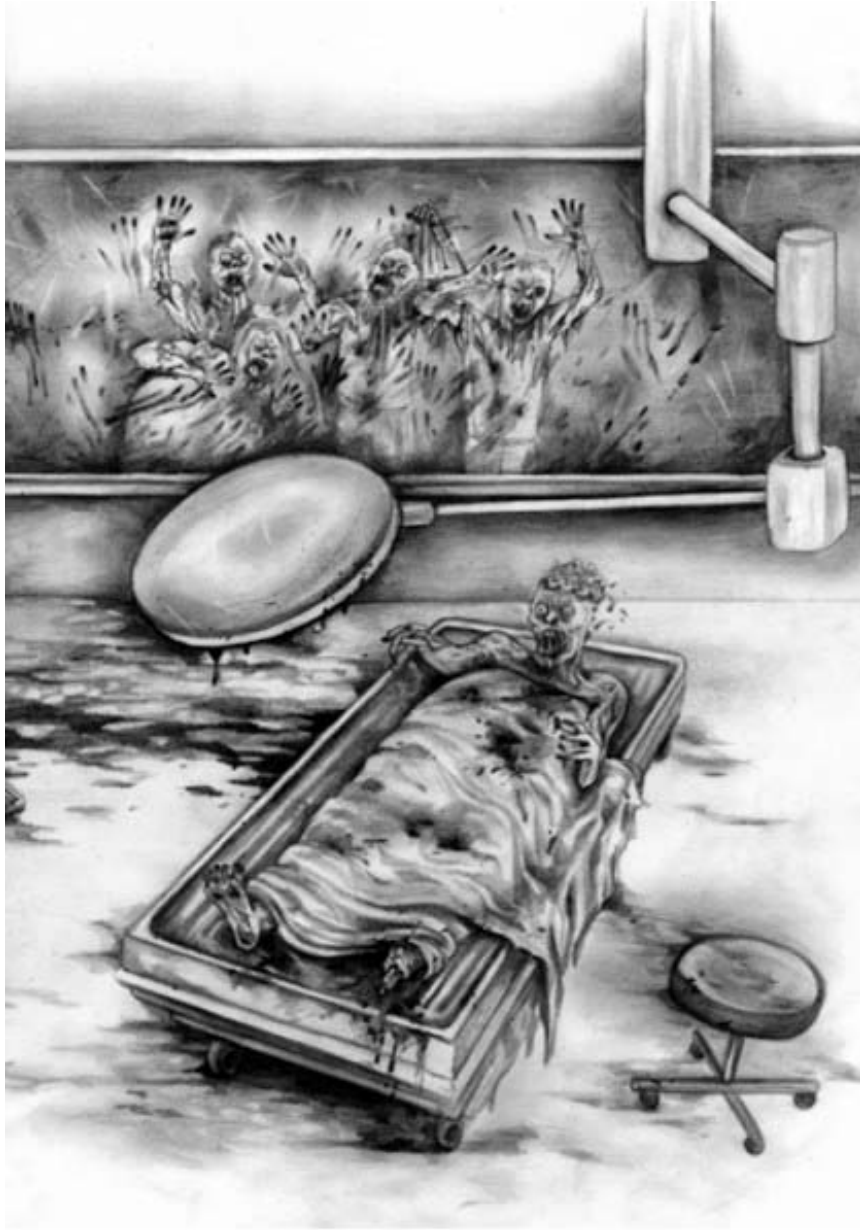ANSD Virus



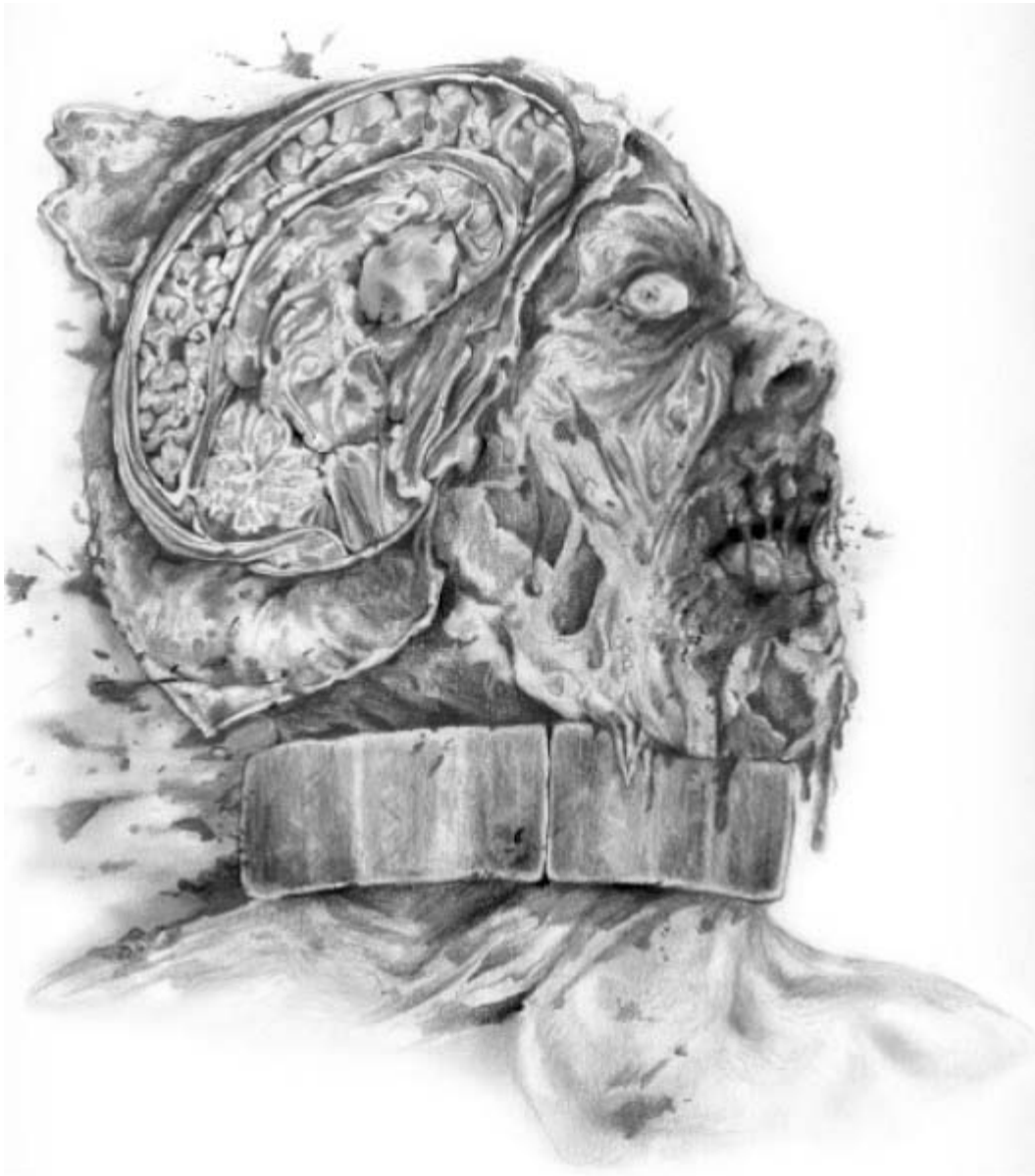The Laboratory



The Laboratory



Note the widened sulci suggesting profound cortical deterioration.



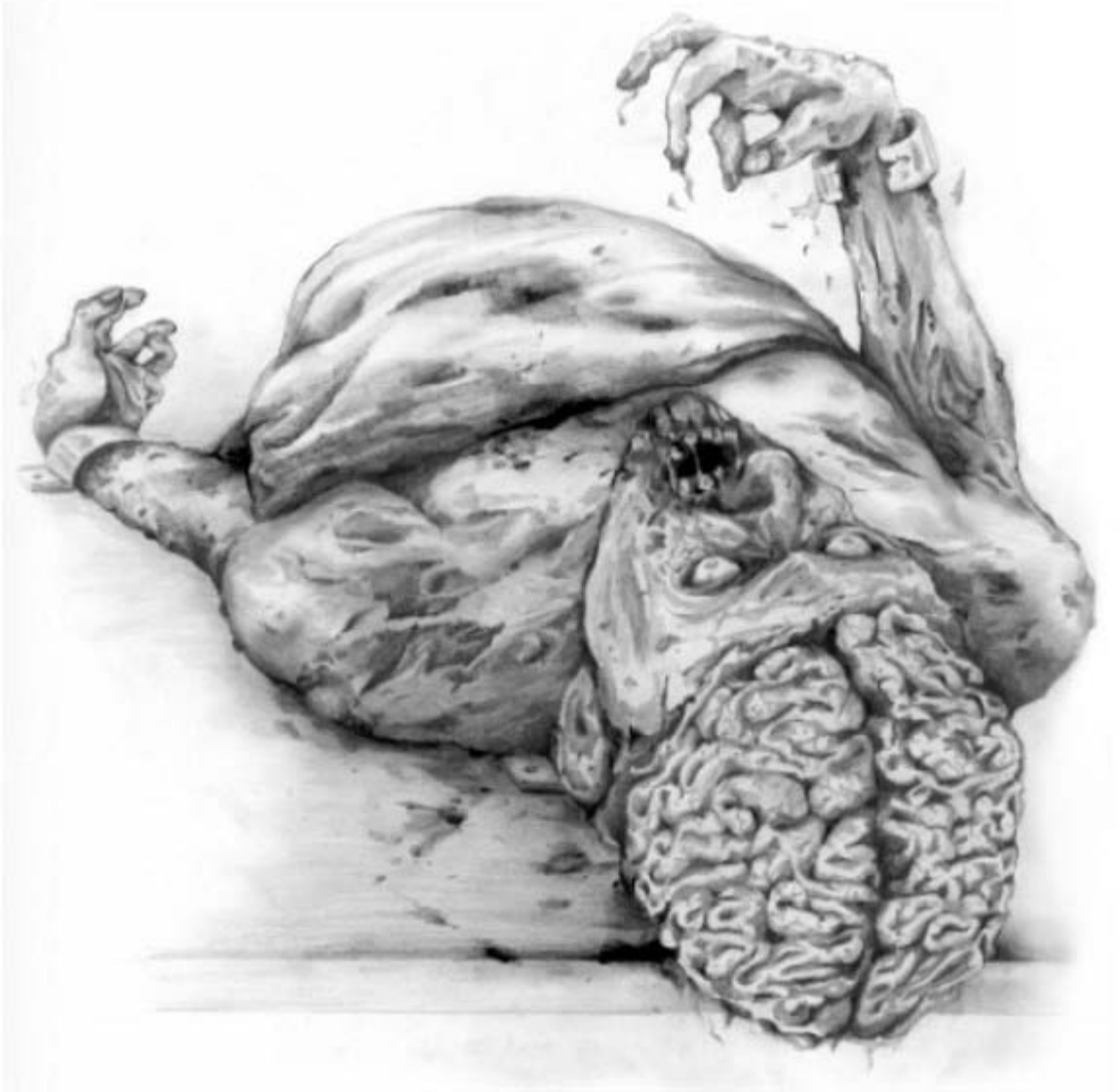Note the activity of muscles of mastication that seem unaffected by ongoing dissection.



Removal of left ear from subject in holding area.



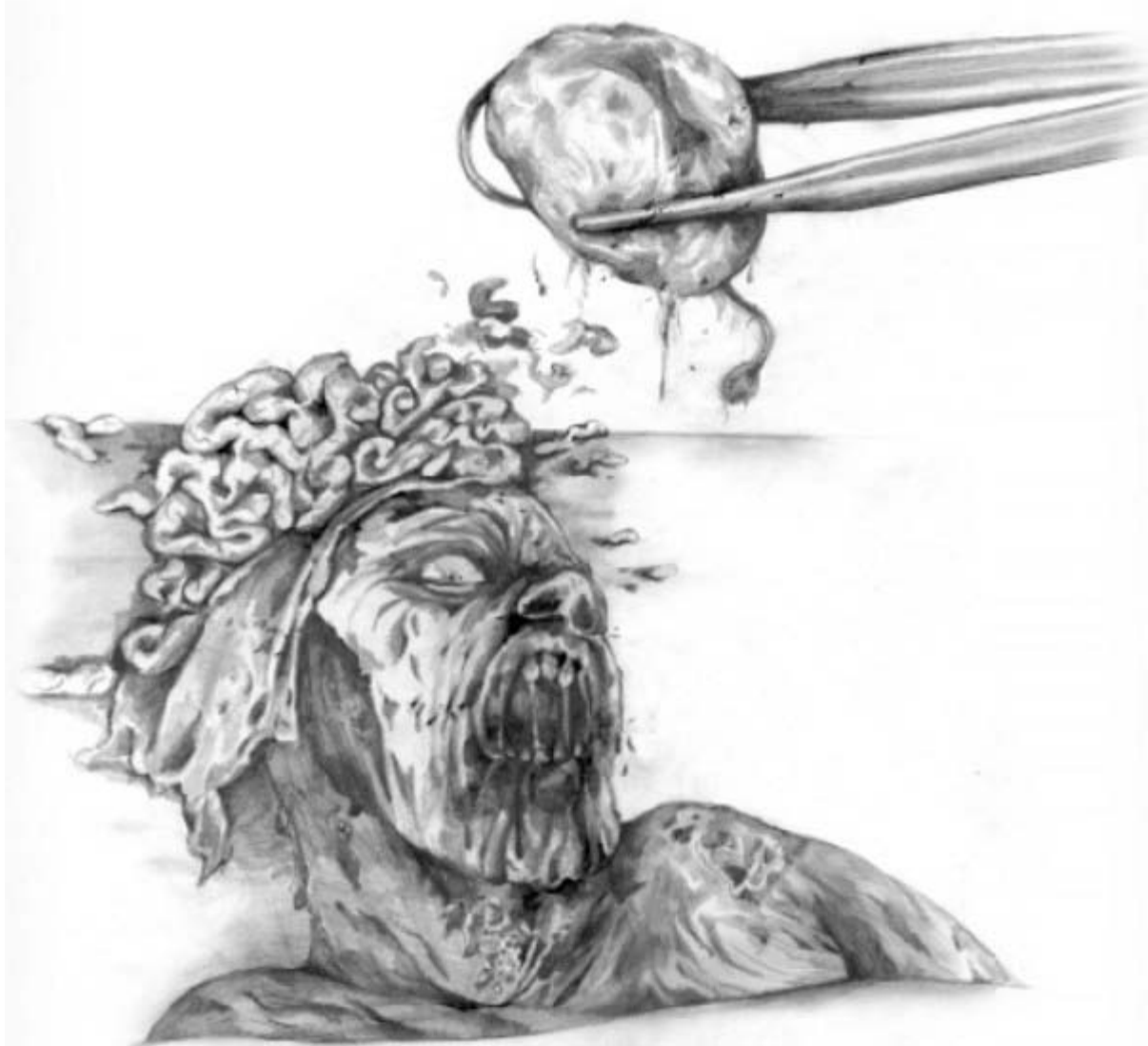Note the widened sulci and loss of neuronal architecture.



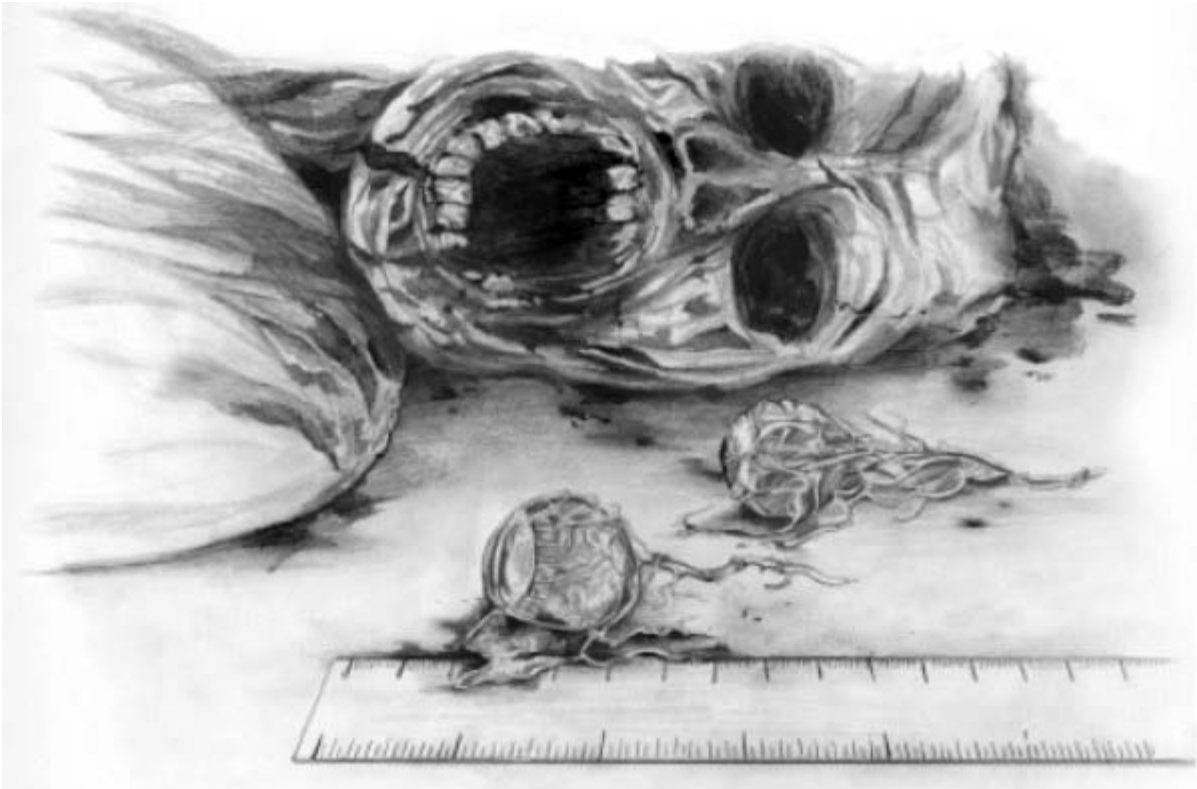
Hypothalamus quickly loses form once removed from connecting brain tissue.



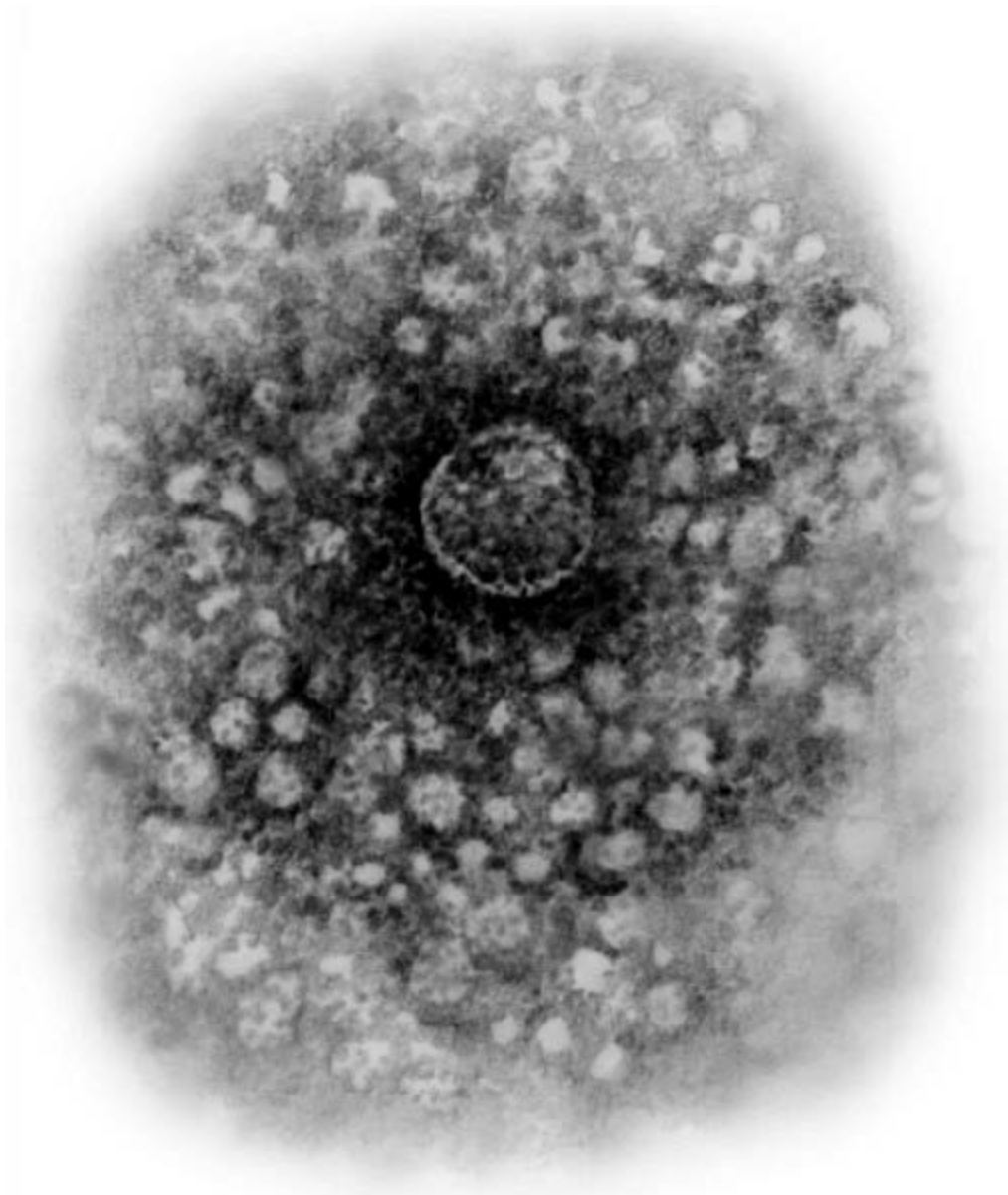
Removal of amygdaloid material.



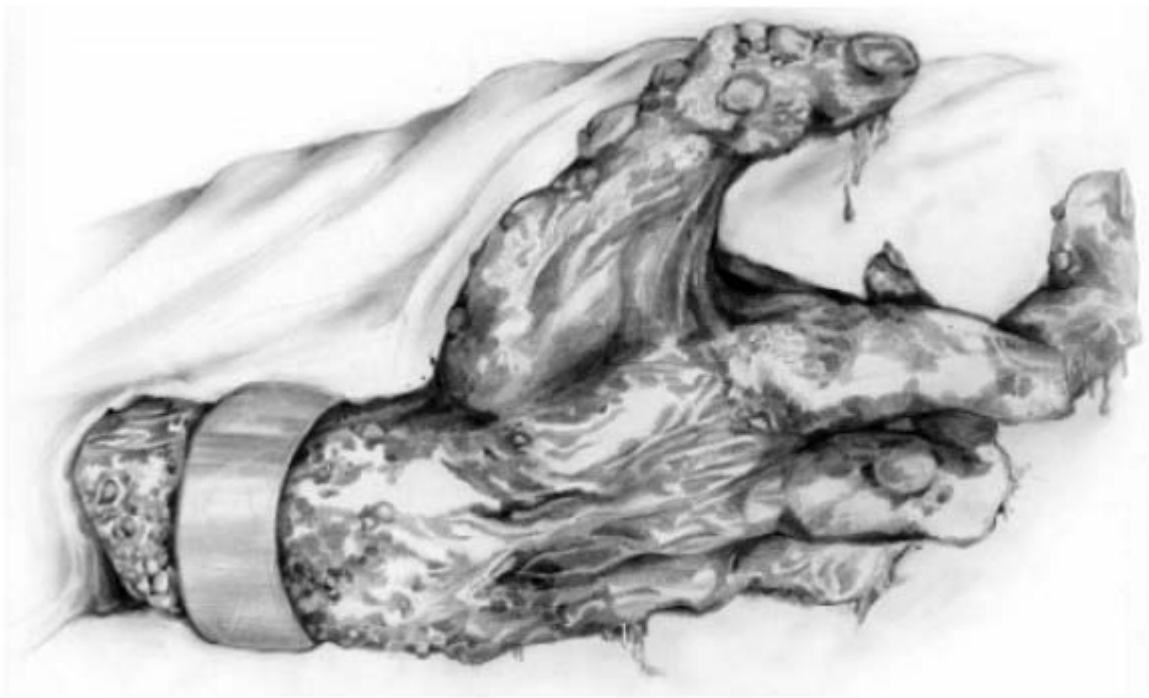Removal of intact eyes and optic nerves.



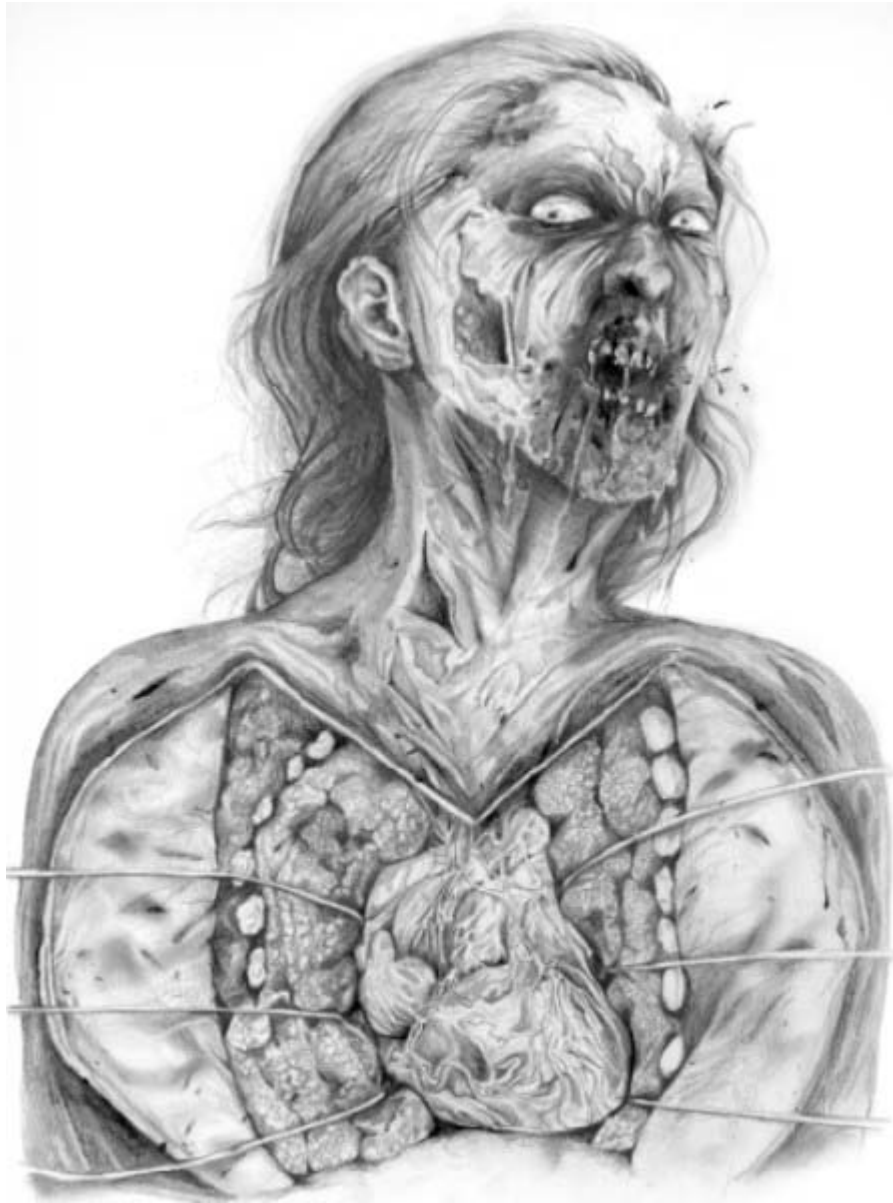Unknown molecular structure found on Gutierrez's computer monitor.



Note the presence of external infection and friable tissue visible along the skin of the restrained hand.



Note the enlarged heart and decaying rib cage. Subject seems unaware of surgical status.



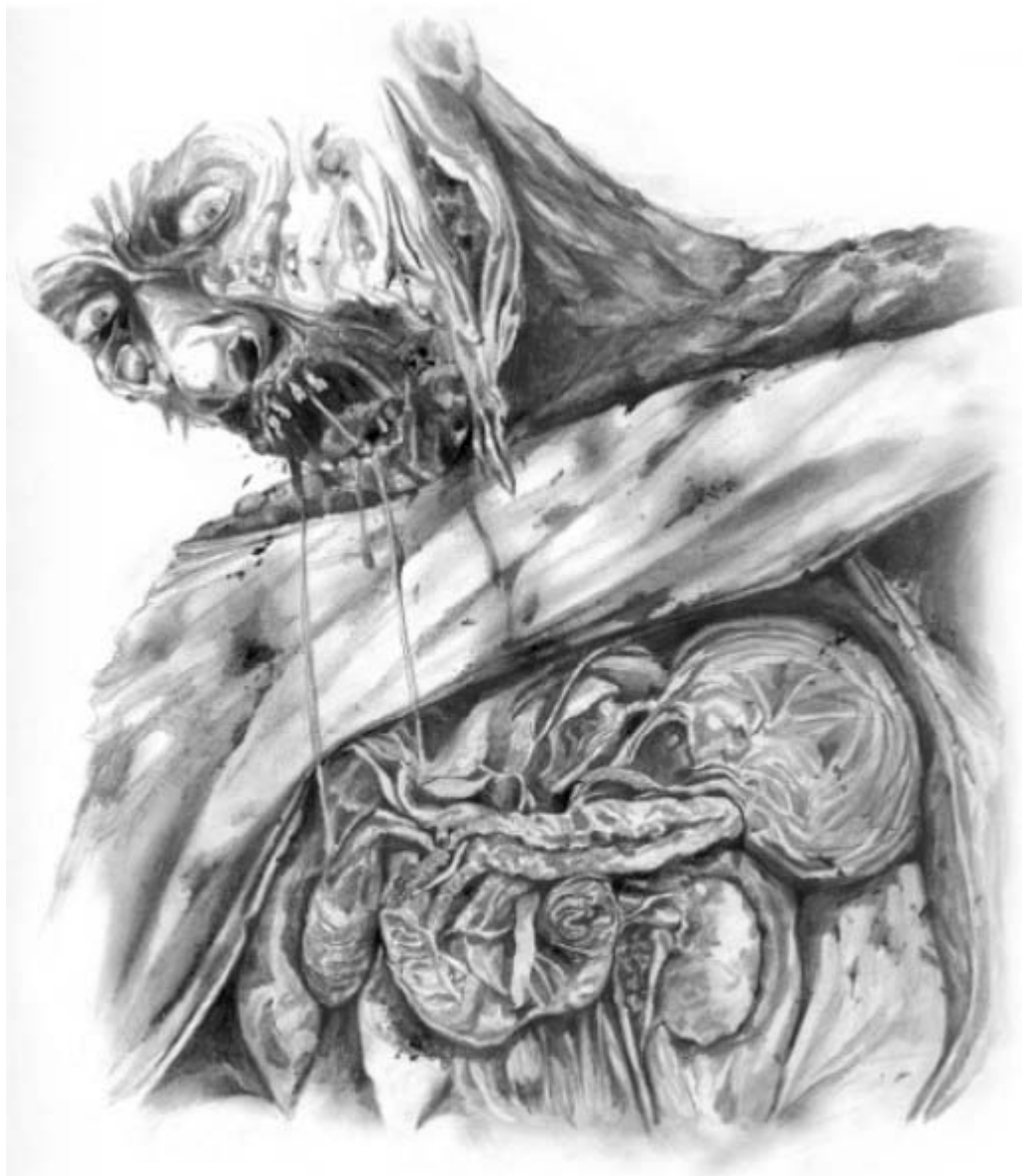Muscles are atrophied, but . . .



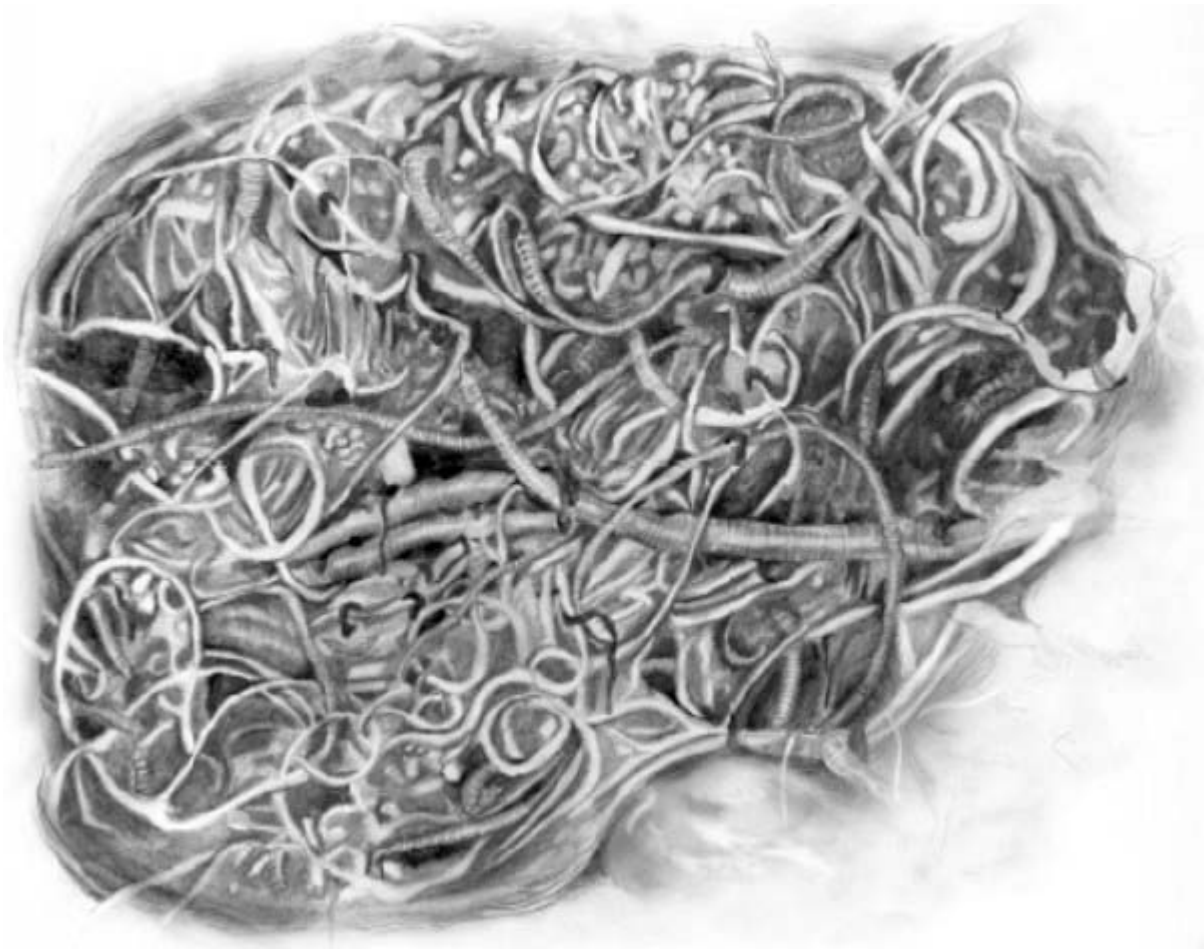
... rudimentary motor control remains present.



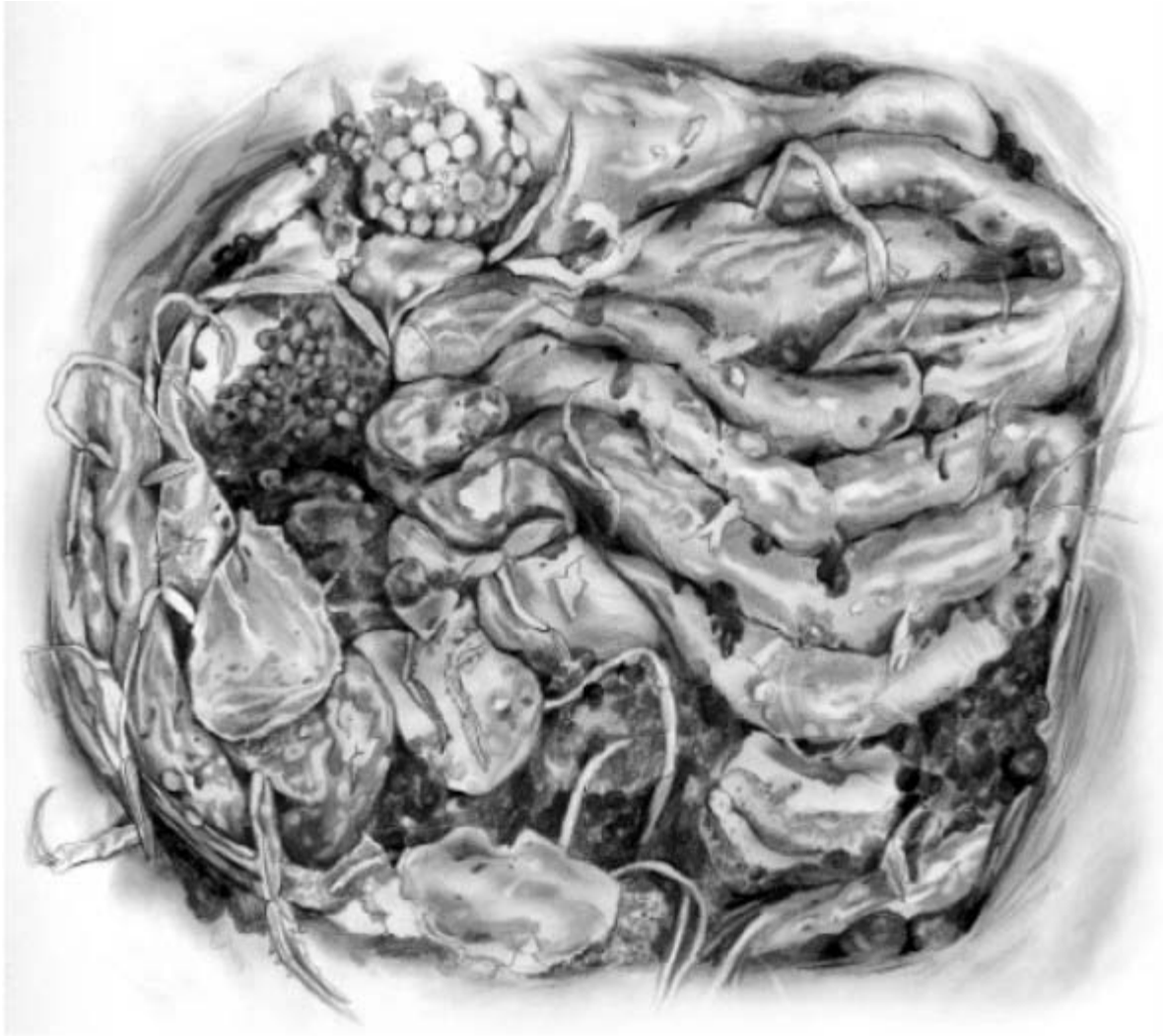Spleen is enlarged and displaced.



Opened abdominal cavity with parasitic worms and bowel perforations.



Small bowel removed showing ongoing presence of tapeworms throughout open cavity.



Appendix VII: Flow Chart for Implementation and Possible Outcomes for Treatment of ANSD

